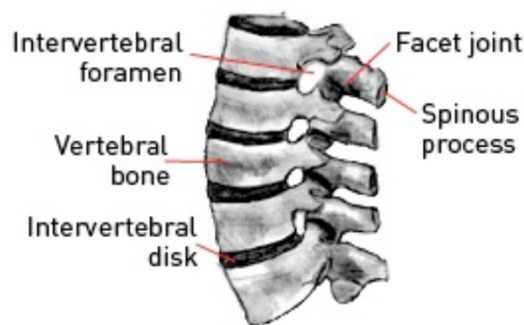


## Lumbar Disc Prolapse

The human spine consists of alternating bony vertebrae and intervertebral discs extending from the neck to the coccyx. The lower portion of the spine is called the lumbo-sacral spine and this bears the majority of weight when we are in the upright position.

The intervertebral discs are the 'shock absorbers' of the body and are composed of an outer strong fibrous membrane and an inner 'jelly-like' nucleus giving both strength and elasticity.

A disc prolapse occurs when there is a weakening in the outer membrane leading to a protrusion of the inner nucleus. This protrusion usually heads postero-laterally towards the spinal canal which contains the nerve roots.



### CAUSE

There is no known cause of lumbar disc prolapses, however it is a degenerative disease, more common in the older generation. Heavy lifting and straining may exacerbate the condition. Some people are predisposed to disc prolapses. The likelihood of having a disc prolapse is slightly higher once a person has had one disc prolapse.

### SIGNS & SYMPTOMS

A variety of symptoms are present with lumbar disc prolapse. These include:

- **Back Pain** – Acute low back pain radiating to the hips and buttocks may be present with an acute disc prolapse. This is due to the sensory innervation of the disc annulus itself. There will often be associated muscle spasm, aimed at limiting movement of the back and relieving pain. However, spasm in itself may cause low back pain.
- **Sciatica** – A postero-lateral disc prolapse may result in pressure on the exiting nerve roots. The nerve roots supply power and sensation to the legs and severe sciatica (pain shooting into the leg) may occur in a specific nerve distribution. Numbness and tingling may also occur in the same region.
- **Cauda Equina Syndrome** – A large or central disc prolapse may result in pressure on the lower part of the spinal nerves called the cauda equina. This may result in cauda equina syndrome which includes:
  - Numbness around the bottom and anus
  - Impotence or sexual dysfunction.
  - Loss of bowel or bladder control.

### INVESTIGATIONS

- Plain X-Rays – these are usually taken to rule out any fracture or malalignment. Dynamic x-rays taken in flexion and extension may be performed to document any instability. Plain x-rays do not give any information on nerve root or spinal cord compression.
- CT L-Spine – this is usually ordered by the GP for back pain and sciatica symptoms. It gives some information on bony alignment but often fails to demonstrate a disc prolapse. Occasionally it is combined with a myelogram to demonstrate any functional compression/obstruction.
- MRI Lumbar Spine – this is the gold standard in looking for lumbar disc prolapses and to delineate the degree of nerve root or cauda equina compression.

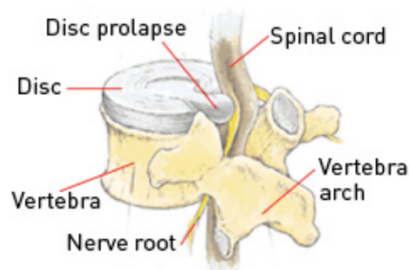


Image © Martin Dunitz 2001, from Sports Injuries: Their Prevention and Treatment, 3rd Edition, by Lars Peterson and Per Renstrom, published by Martin Dunitz Ltd, www.dunitz.co.uk

### TREATMENT

The presence of intractable radicular pain and neurological deficit is an indication for operative neurosurgical treatment. Neurosurgical treatment aims to relieve symptoms via decompressing nerve and with or without stabilising the spine (fusion).