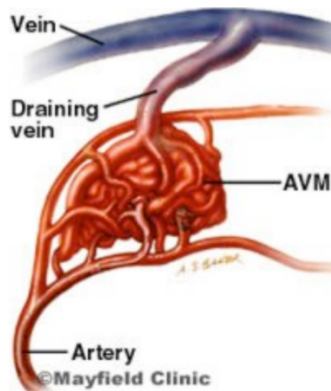




## Intracranial Arteriovenous Malformation (AVM)

A vascular malformation is an abnormal collection of blood vessels with direct blood flow from the arterial system to the venous system. There is a lack of the normal interposed capillary vessels. This renders the vessels fragile and at risk of bleeding or forming aneurysms.



Copyright © Mayfield Clinic

### CAUSE

AVMs are present from birth making them congenital lesions. There are numerous theories as to their cause and timing of development, but nothing has been confirmed. Most AVMs are discovered in people aged 20-40 however they are also the most common cause of subarachnoid haemorrhage in the paediatric population.

### SIGNS & SYMPTOMS

AVMs may be discovered incidentally on a routine CT or MRI of the brain for another reason. They most commonly present following haemorrhage which may be intracerebral, subarachnoid, intraventricular or a combination of all. Other presentations include mass effect, ischaemic symptoms from steal phenomenon, audible bruits and raised intra-cranial pressure.

The symptoms related to these are dependent on the site of the AVM and include:

- Headaches, nausea and vomiting.
- Bruit – an abnormal swishing or ringing sound in the ear caused by blood pulsing through the AVM.
- Visual disturbance.
- Neck stiffness, light and sound intolerance.
- Seizures.
- Neurological deficits which may include weakness, numbness and speech disturbances – this can be progressive or transient.
- Loss of consciousness or confusion.
- Coma and death.

### INVESTIGATIONS

- CT Head – this will demonstrate the AVM as well as any other haemorrhage associated with it. The AVM may be calcified and mass effect may be evident.
- CT angiogram – this may be performed at the same time of a CT head to give high resolution pictures of the blood vessels and provide a further tool for diagnosis and surgical planning.
- MRI/MRA – this may occasionally be performed to demonstrate the flow in the cerebral blood circulation and diagnose AVMs. With the progression of CT angiogram technology this is becoming less commonly used.
- Digital subtraction angiogram (DSA) – this is the gold standard currently in delineation of the entire cerebral blood vessels and allows treatment by intravascular techniques (ie coiling, gluing) if suitable. It also allows diagnosis of any intra-cranial aneurysms that may be associated.



**Brendan O'Brien**  
NEUROSURGERY

**Neurosurgeon and Complex Spinal Surgeon**  
MBBS Hons FRACGP FRACS MAICD

A: 378 Victoria Parade, East Melbourne VIC 3002

T: 03 9417 5033

F: 03 9960 2763

E: [admin@brendanobrien.com.au](mailto:admin@brendanobrien.com.au)