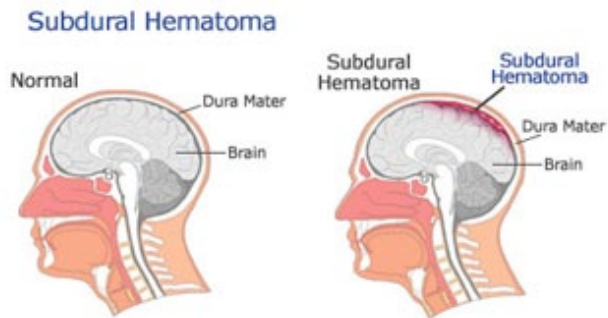


Subdural Haematoma



© Dementia Information Page: www.about-dementia.com

The brain is surrounded by a strong protective membrane called the meninges. The meninges themselves are composed of 3 distinct layers, the dura, arachnoid and pia from superficial to deep. Potential spaces occur between these layers and if sufficient force is applied, blood can accumulate within these spaces.

A subdural haematoma is a collection of blood beneath the dural layer of meninges.

It may be:

- acute (<2 days),
- subacute (2-14 days) or
- chronic (>14 days).

The difference lies in the composition of the clot which degrades and becomes more liquid over time. Treatment is dependent on the severity of symptoms, the size and type of haematoma on presentation.

CAUSE

This is most commonly caused by:

- Trauma related to a fall or motor vehicle accident. The trauma related to chronic subdural haematomas may be very minor.

It can also occur spontaneously in unusual cases of:

- superficial vascular malformations,
- in patients taking blood thinning medication (eg clopidogrel, warfarin) or
- patients with haematological conditions, which affect clotting eg haemophilia.

SIGNS AND SYMPTOMS

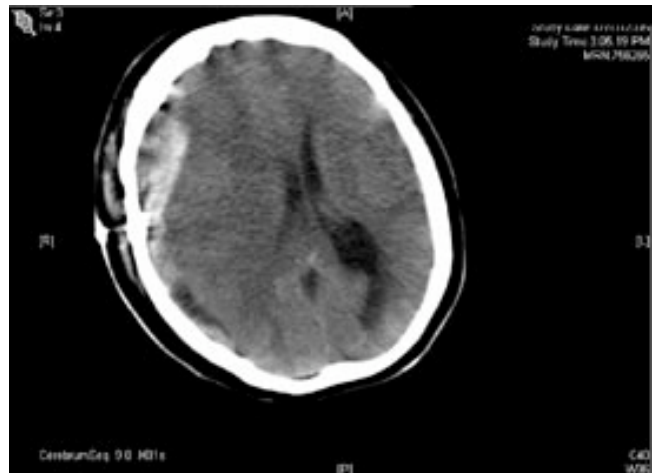Patients complain of a variety of symptoms including:

- Headache – this is the most common symptom of a subdural haematoma.
- Stroke-like symptoms – these include abnormal speech, weakness and numbness due to localised pressure. Often the patients are unaware of their deficit which is identified by a close friend or relative.
- Altered consciousness/coma – large acute subdural haematomas may result in raised intracranial and cause loss of consciousness

In traumatic subdural haematomas there will often be associated brain and other organ injuries leading to altered consciousness, even coma and respiratory arrest.

Investigations

The investigation of choice for a subdural haematoma is a rapid multislice CT of the head.



CT scan demonstrating acute subdural haematoma.