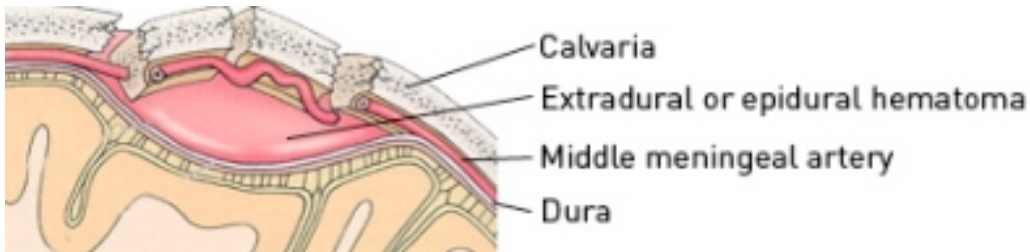


Extradural Haematoma



Extradural Haematoma © USCNeurosurgery

The brain is surrounded by a strong protective membrane called the meninges. The meninges themselves are composed of 3 distinct layers, the dura, arachnoid and pia from superficial to deep. Potential spaces occur between these layers and if sufficient force is applied, collections of blood can accumulate within these spaces.

An extradural haematoma is a collection of blood between the skull and outer layer of dura.

CAUSE

It is most common in younger patients as a result of high impact head trauma. There is usually an overlying skull fracture and damage to a superficial artery leading to the collection of blood.

SIGNS AND SYMPTOMS

- Headache – patients will often complain of a headache.
- Focal neurological deficits - there can be stroke-like symptoms like abnormal speech, weakness, and numbness due to localised pressure on the brain.
- Classically there may be a lucid period immediately following the injury before a sudden deterioration leading to altered consciousness, even coma and respiratory arrest. As such prompt treatment following diagnosis is imperative.

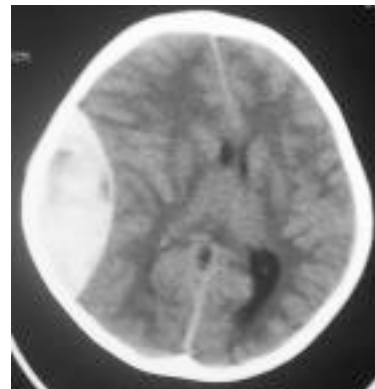
INVESTIGATIONS

Blood tests

There are no specific blood tests to diagnose an extradural haematoma. Routine FBE, electrolytes and clotting profile will be performed prior to operative evacuation of an extradural haematoma.

Radiological tests

- Skull X-Ray – this may demonstrate an associated skull fracture overlying the extradural haematoma.
- CT head – this is the investigation of choice being fast and readily available. The use of bony windows will help demonstrate the presence or otherwise of an overlying fracture.



CT Head demonstrating large extradural haematoma