

## Brain Tumours

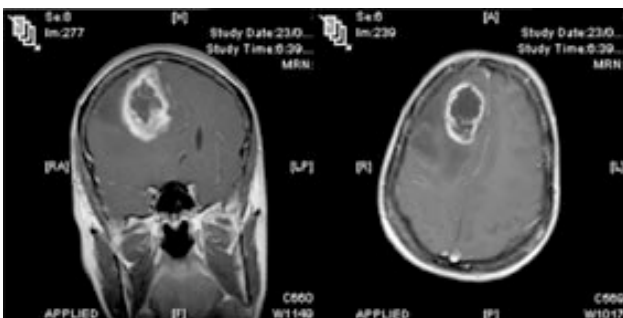
Brain tumours are made of cells growing and reproducing in an uncontrolled fashion. A benign brain tumour is formed from abnormal cells that form a distinct boundary from the surrounding normal brain. A malignant brain tumour is dangerous because it consists of cancerous cells growing into adjacent brain tissue so that it may no longer function normally. The life threatening nature of a malignant brain tumour depends on both the type of cancerous cells that comprise the tumour and the exact location of the tumour in the brain.

Tumours that arise from cells found normally in the brain are primary brain tumours while metastatic brain tumours are formed by cancer cells originating from a cancer in another part of the body such as lung or breast cancer.

### TYPES OF MALIGNANT BRAIN TUMOURS

#### Astrocytoma

These tumours arise from star-shaped cells called astrocytes that normally serve as supportive tissue for brain cells. These tumours may behave with different degrees of malignancy or invasiveness that may be described as low-grade, mid-grade or high-grade, or, alternatively as grade I to grade IV. The most life threatening type of astrocytoma is grade IV and is also known as glioblastoma multiforme. Astrocytomas may occur in several different parts of the brain, such as the cerebral hemispheres containing the frontal, parietal, temporal and occipital lobes, in the brainstem when it is called a brainstem glioma, or in part of the visual pathway when it is called an optic nerve glioma.



*Left – Coronal MRI of Glioblastoma Multiforme  
Right – Sagittal MRI of Glioblastoma Multiforme*

#### CNS Lymphoma

CNS lymphoma may affect previously healthy individuals or patients who have compromised immune systems. These tumours are treatable with radiation and/or chemotherapy but histological diagnosis is required prior to treatment.

#### Ependymoma

This tumour type arises from cells that usually form the lining of the fluid-filled cavities of the brain (ventricles). Ependymomas may occasionally spread to another location in the central nervous system or originate in the spinal cord.

#### Medulloblastoma

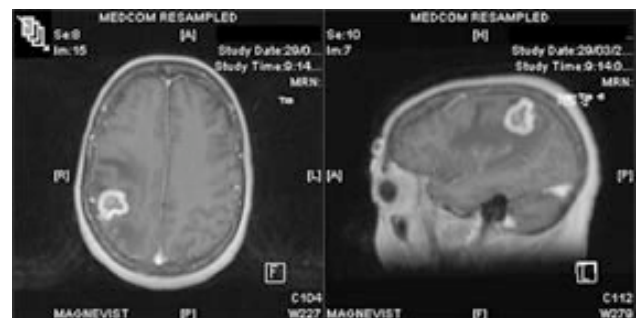
Medulloblastomas are the second most common type of brain tumour in children but may also occur in adults. These tumours are located in the cerebellum and may cause symptoms of clumsiness, headaches and nausea.

#### Pineal Region Tumours

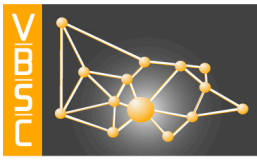
These are rare tumours deep in the substance of the brain. They are often germ-cell tumours and have a propensity to seed through the CSF into the spinal region. Usually there will be elevation of tumour markers in the CSF. Occasionally pineal region tumours are associated with pituitary tumours.

#### Metastatic Brain Tumours

Metastatic brain tumours occur more frequently than primary brain tumours. These malignant brain tumours are formed by cancer cells that originated from a cancer growing in a separate organ of the body before spreading to the brain. The malignant tumours that spread most often to the brain are lung cancer, breast cancer, skin melanoma, and renal (kidney) cancer. Metastatic brain tumours may be single or multiple and can occur in the cerebral hemispheres or cerebellum.



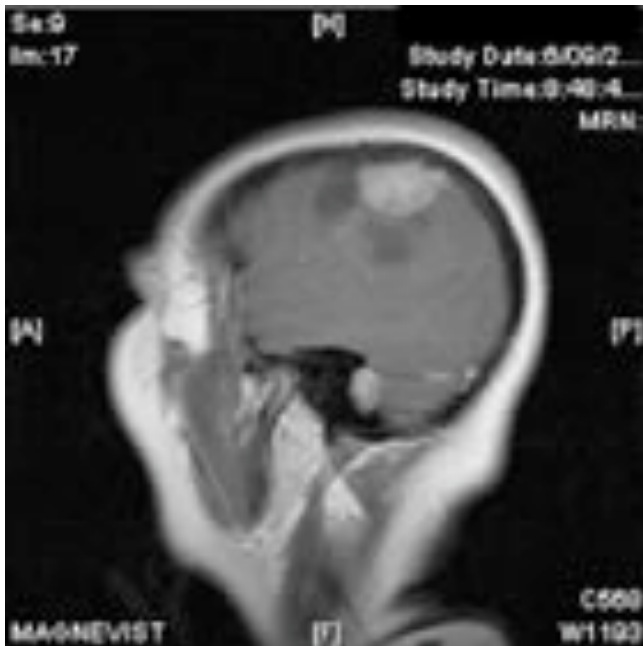
*Left – Axial MRI of breast metastasis  
Right – Sagittal MRI of breast metastasis*



## TYPES OF BENIGN BRAIN TUMOURS

### Meningioma

This tumour arises from the strong covering layers surrounding the brain called the meninges. In general it is slow growing and causes symptoms by localized pressure on the brain. Meningiomas do not frequently invade into the brain or spread. Depending on the size and site of the meningioma treatment may involve monitoring with regular scans, neurosurgery or radiosurgery.



*Sagittal MRI of meningioma*

### CAUSE

In many cases there is no known cause for the brain tumour. Previous head trauma is not a cause of brain tumours. Metastatic brain tumours will often have a known primary tumour site, most commonly arising from lung, breast, skin, colon and kidney.

There are a small proportion of the population with a genetic predisposition to getting brain tumours. These patients will often present with multiple tumours and a family history of tumours. These are unusual cases.

## SIGNS AND SYMPTOMS

A tumour growing in the brain will eventually cause pressure and subsequent damage on adjacent normal brain. The symptoms depend on the size and location

of tumour, as well as the mass effect caused by the abnormal space-occupying lesion and may include:

- Raised intracranial pressure.
- Focal neurological deficits.
- Seizures.
- Raised intracranial pressure.
- Headaches, nausea and vomiting, confusion or difficulty concentrating are the result of raised intracranial pressure. With markedly increased pressure, progressive drowsiness and coma can occur.
- Focal neurological deficits. This is dependent on the site of the tumour and may mimic a stroke with weakness, numbness, paralysis, speech impairments, disorientation, difficulty walking and visual disturbance. Personality changes are also seen.
- Seizures. This is due to abnormal conduction of normal brain signals from the tumour presence by direct infiltration and disruption of the conduction channels, or reactive swelling and pressure that cause disruption.

## INVESTIGATIONS

- Blood tests – There are no specific blood tests to diagnose brain tumours. There may be positive tumour markers in the presence of a metastatic brain tumour. A routine FBE, electrolytes and clotting profile will be taken prior to neurosurgical intervention.
- Radiological imaging
  - CT head – this is usually the first-line investigation to diagnose brain tumours
  - MRI head – this is the gold standard for diagnosis of brain tumours giving high detailed definition into the tumour and surrounding neural structures. A stereotactic MRI will be obtained to assist in surgery in most cases. Occasionally an MRI of the spine will also be obtained to determine the presence or otherwise of tumour seeding in the CSF (eg medulloblastoma, pineal tumours).

Lumbar puncture. In the presence of raised intracranial pressure this is contraindicated, however in cases of suspected germ cell tumours it may assist in diagnosis and treatment planning by giving levels of AFP, beta-HCG